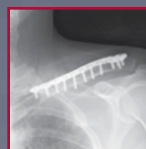
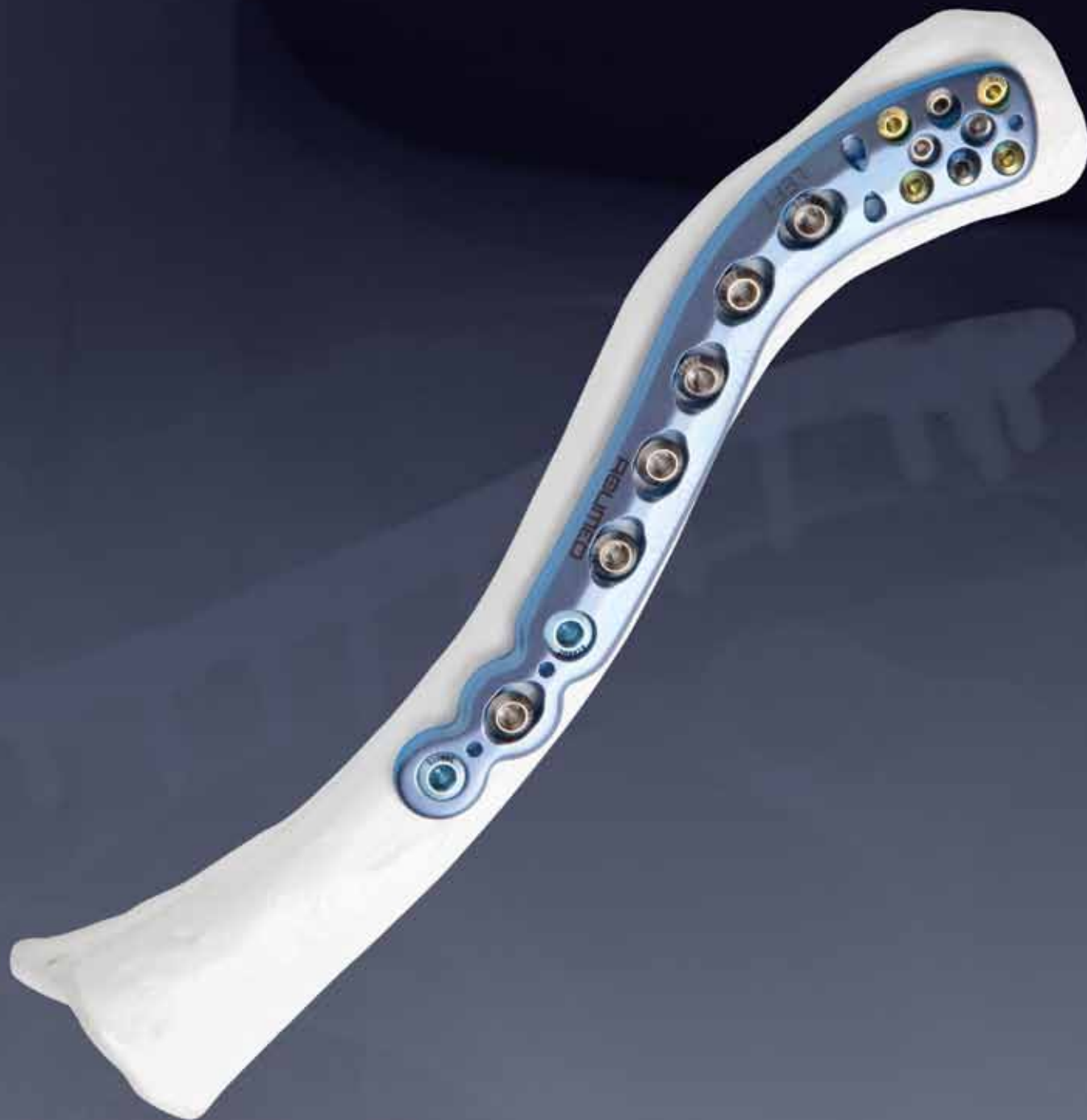

ACUMED[®]

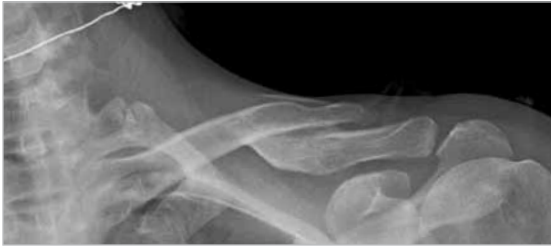Innovative Solutions



Locking Clavicle
Plating System

Locking Clavicle Plating System

Since 1988, Acumed has been designing solutions to the demanding situations facing orthopaedic surgeons, hospitals and their patients. Our strategy has been to know the indication, design a solution to fit, and deliver quality products and instrumentation.



In 2003, Acumed launched an innovative solution for repairing fractures of the clavicle by designing the first truly anatomic clavicle plate. Soon after, the Locking Clavicle Plate System was introduced and quickly became a market leader thanks to many pioneering features including:

- Pre-contoured plate geometry
- Multiple plate options
- Beveled edges to minimize soft tissue irritation
- Tubularized undersurface for additional torsional stability
- Specialized instrumentation to prevent injury to subclavian vessels

Acumed's goal was to provide a comprehensive solution for repairing fractures located from the middle third to distal third of the clavicle. This was in recognition that traditional hardware used in standard ORIF procedures for clavicle fractures including pinning, reconstruction and Dynamic Compression plating have historically provided less than desirable results including soft tissue irritation and/or failure prior to union, requiring a second procedure.¹

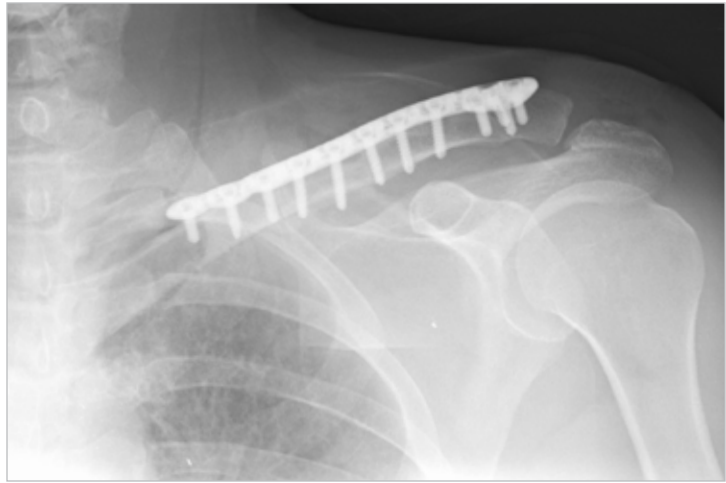
This versatile system is used to treat many acute clavicle injuries including simple to complex midshaft fractures, transverse fractures, comminuted fractures, open fractures and displaced, isolated fractures of the distal clavicle. In addition to acute injuries, Acumed's plates provide excellent fixation for malunions and symptomatic non-unions of the clavicle.

X-ray's in this brochure are courtesy of:

William B. Geissler, M.D.

Grant Padley, M.D.

Anthony Timms, M.D.



Since its introduction, surgeons have utilized the Acumed Locking Clavicle Plate System to solve many complex injuries of the midshaft and distal clavicle.

Designed in conjunction with William B. Geissler, M.D., Acumed's line of Locking Clavicle Plates for plating the superior aspect of the clavicle have long been recognized for offering a low profile solution. Pre-contoured to match the natural S-shape of the clavicle, this titanium plate offers increased strength with a rounded profile and a low profile plate-screw interface. This design not only reduces OR time spent in contouring a plate but minimizes soft tissue irritation for the patient.

In line with our goal to bring to the market products that evolve and improve patient outcomes, Acumed introduces three additional plate designs to the system: Locking Straight Plate, Locking Distal Clavicle Plates and Locking Anterior Clavicle Plates.


The **Locking Straight Plate** provides an additional option for midshaft clavicle fractures. This addition rounds out the selection of midshaft plates cited for addressing 94%-98% of the patient population² and further enhances a surgeon's ability to treat patients with a smaller bone structure.

The redesigned **Locking Distal Clavicle Plate** offers an improved solution to treat complex lateral third clavicle fractures that cause disruption of the coracoclavicular (CC) ligaments. The screw positioning and angulation of these plates targets the distal fragments and provides secure, stable fixation for multiple fracture patterns.

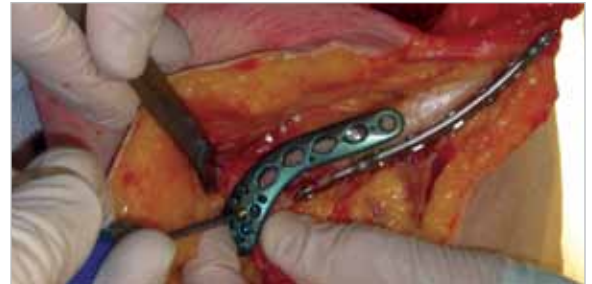The **Anterior Locking Clavicle Plate** was developed for orthopaedic trauma surgeons who understand the mechanical, biological and technical principles of plating. These pre-contoured, anatomic plates are designed for surgeons who desire an anterior approach perceived to minimize risk, increase screw purchase in bone and reduce potential hardware prominence.

Locking Clavicle Plating System

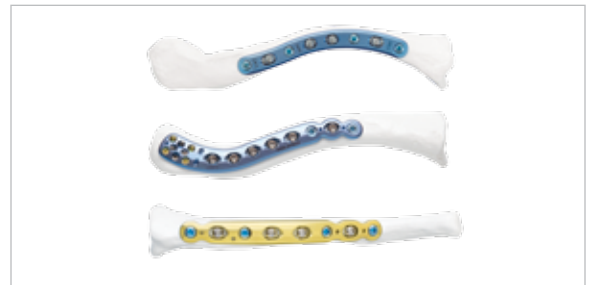
Pre-contoured Anatomic Plate Design assists in restoring the original geometry of the patient's anatomy with little or no bending. Acumed's goal was to design a plate that most closely replicated the anatomical contours of the clavicle to maximize support and accurately reduce the fracture. The plate may also act as a template for restoring the patient's original anatomy when reconstructing a malunion, non-union or a highly comminuted fracture unlike intramedullary rods/pins or straight plates.



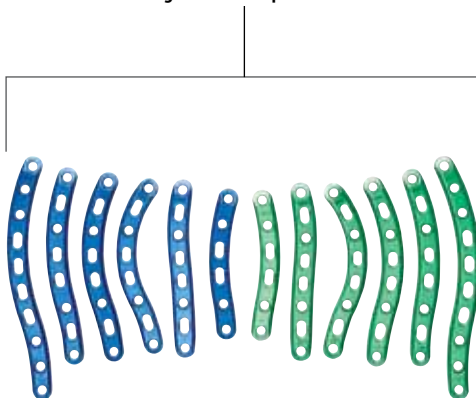
Extensive Cadaveric Research and Clinical Experience aided in the development of multiple anatomically contoured, low profile plate options available to fit a wide variety of clavicle curvatures. For central one-third applications, six different lengths and curvatures are available in both left (blue) and right (green). Eight additional left and right specific plate options are included to precisely match the anatomic curvature of the distal clavicle. To round out the system, five anterior plates have been developed for both medial and lateral applications.



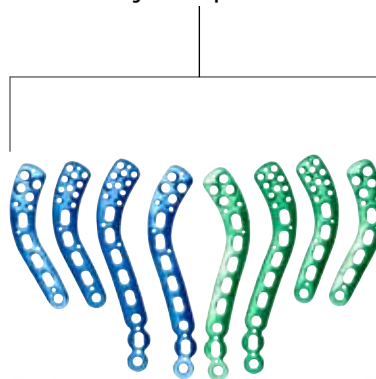
"Approach-Specific" Plates for the clavicle provide the surgeon with the option to choose his/her preferred surgical approach (superior or anterior), providing a complete clavicle plating solution with a straightforward surgical technique. Plate families are color-coded for quick distinguishing in the OR. User-friendly, innovative instrumentation aids to further simplify the technique for the surgeon.




Locking Midshaft Superior Plates



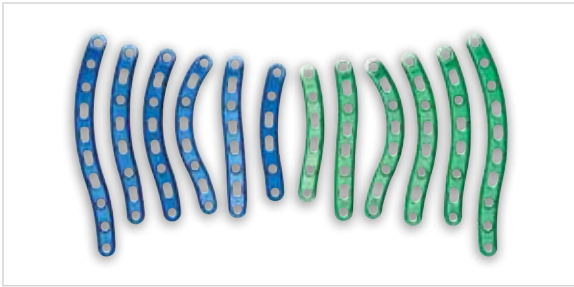
Locking Distal Superior Plates



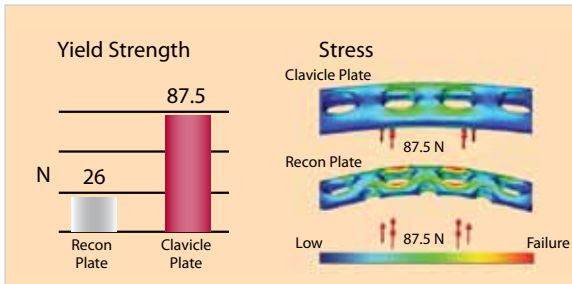
Locking Anterior Plates



Superior Locking Midshaft Plates



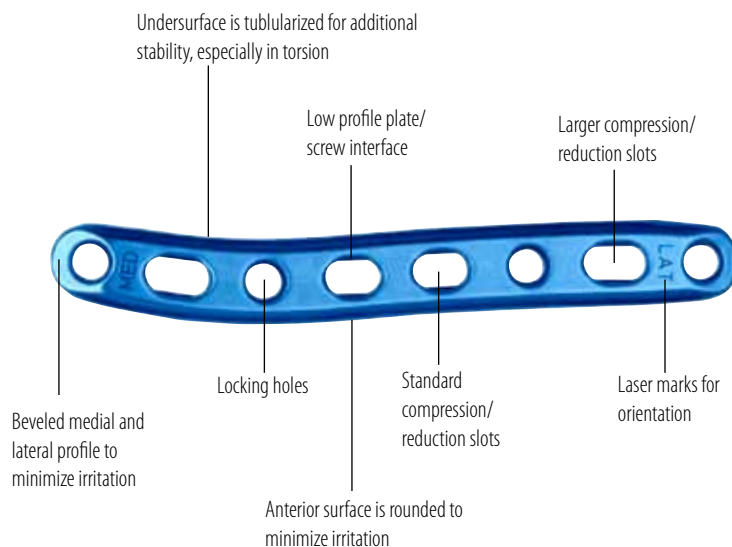
Multiple Pre-contoured Plate Options are available to fit a wide variety of midshaft clavicle curvatures and restore the original geometry of the patient's anatomy with little or no bending. Surgeons may choose from twelve superior midshaft plates designed to address central one-third applications. Available in six different lengths and curvatures in both left (blue) and right (green), these plates act as a template when reconstructing a malunion, non-union or a highly comminuted fracture unlike intramedullary rods/pins or straight plates.



Superior Biomechanical Stability is engineered into both the design of the plates and their orientation on the clavicle. Plating the superior aspect of the clavicle has been found to be biomechanically the most stable³. Acumed's in-house analysis showed that when subjected to equal force, a 3.5mm Stainless Steel reconstruction plate broke in multiple locations while Acumed's clavicle plate suffered no permanent deformation⁴.



Low Profile Plate Design minimizes the possibility of post-operative soft tissue irritation and patient discomfort. Features include beveled medial and lateral profiles with rounded anterior and posterior surfaces to minimize soft tissue irritation. A tubularized undersurface allows the plate to sit flush on the bone and provides additional stability, especially in torsion. Locking and non-locking screws sit flush with the plate. Tapered plate ends reduce the risk of bone refracture above or below the plate due to excess stress concentrations.

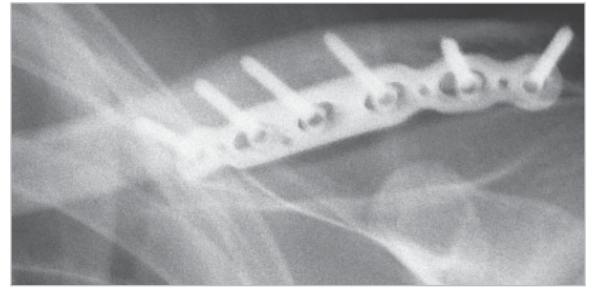


All plates have a combination of compression slots and locking holes for maximum fixation

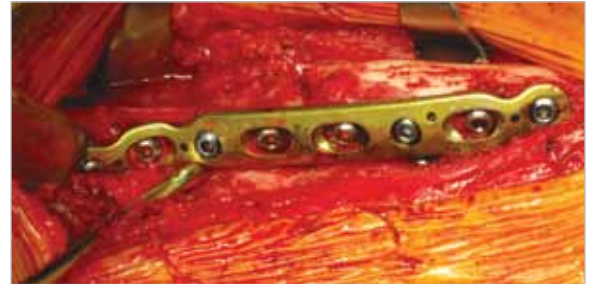8-hole Locking Clavicle Straight Plate shown

Anterior Locking Clavicle Plates

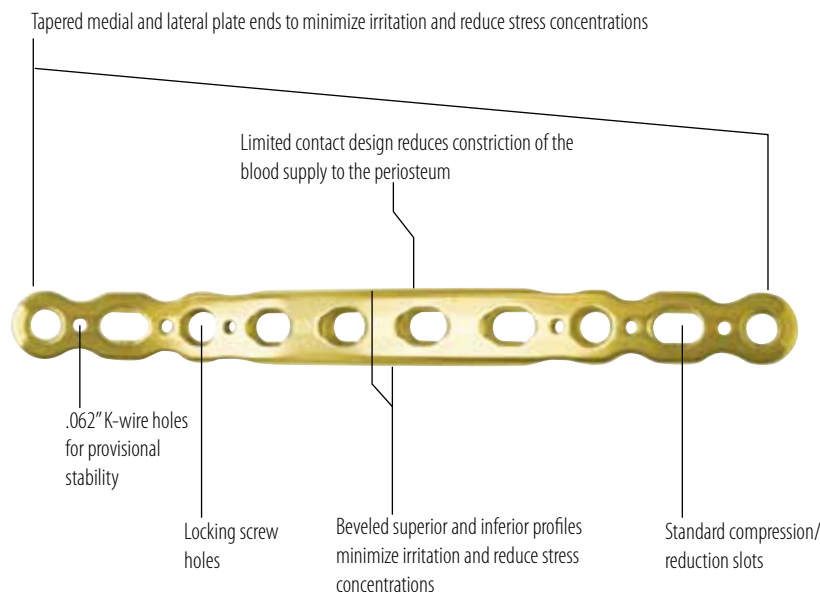
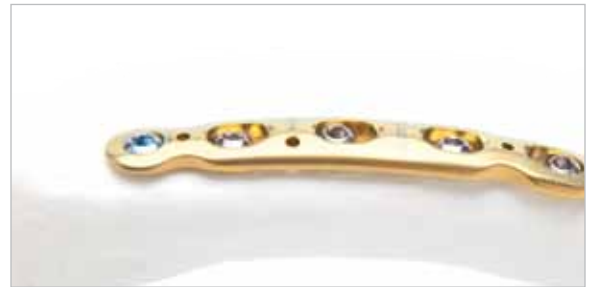“Anterior-Specific” Plates for the clavicle provide the surgeon with the option to choose his/her preferred surgical approach, providing a complete clavicle plating solution with a straightforward surgical technique. Often cited advantages to using an anterior plate to treat clavicle fractures include increased bone stock for maximized screw purchase, reduced prevalence of soft tissue irritation, and a safer approach as instrumentation is directed away from vital subclavian vessels. Acumed's Anterior Clavicle Plates are color-coded gold for quick distinguishing in the OR.



Anatomic Plate Contour assists in restoring the original geometry of the patient's anatomy. Extensive cadaveric research facilitated the development of an anatomically contoured, low profile plate design. This maintains plate strength integrity, decreases valuable OR time and allows the plate to be used as a template to aid with anatomic restoration. Five plates are available in the system in 6-, 8- and 10-hole lengths to more precisely match the anatomical curvature of the clavicle.



Low Profile Plate Design minimizes the possibility of post-operative soft tissue irritation and patient discomfort. Locking and non-locking screws sit flush with the plate. Tapered plate ends reduce the risk of bone refracture medial or distal to the plate due to excess stress concentrations. The limited contact design reduces constriction of the blood supply to the periosteum.



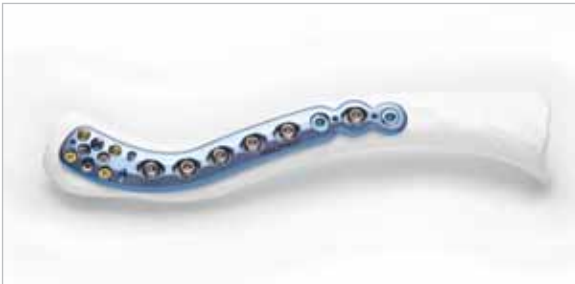8-hole Medial Anterior Locking Clavicle Plate shown

All plates have a combination of compression slots and locking holes for maximum fixation

Locking Distal Clavicle Plates



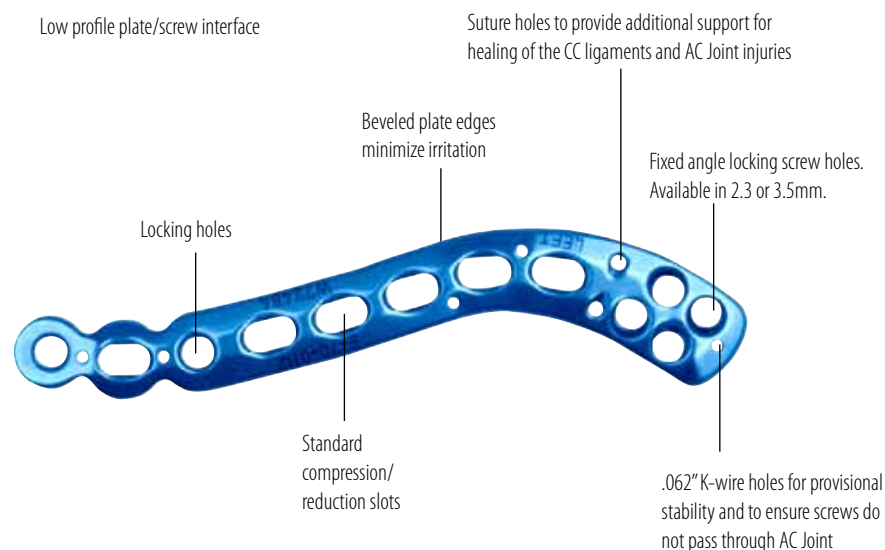
Precise Screw Placement to maximize bone purchase in the distal clavicle. Acumed's distal clavicle plates are designed to be placed more distal than most other clavicle plates. Diverging and converging distal screw configurations maximize bone purchase and increase pullout resistance, especially in axial loads. K-wire holes in the far distal end of the plate allow the surgeon to verify screw and plate placement to ensure the AC joint is not violated. A threaded drill guide ensures that the fixed angle distal screws are properly inserted and seated flush with the plate surface.



Increased Healing Capacity for disruption of the coracoclavicular (CC) ligaments due to musculature and ligamentous deforming forces. Suture holes and compression slots throughout the shaft allow for additional support through adjunct techniques such as banding of the clavicle to the coracoid process or utilization of the Bosworth Screw technique. Tapered plate ends reduce the risk of bone refracture due to excess stress concentrations while the limited contact design reduces constriction of the blood supply to the periosteum.



Multiple Distal Screw Configurations provide treatment options to improve fixation and pull-out strength. Based upon the fracture pattern and his/her preferred approach, a surgeon may choose either an 8- or 4- hole distal plate. The 8-hole plates allow up to eight 2.3mm screws distally, (fully threaded locking and non-toggling). With the 4-hole option, the distal screws (2.7mm or 3.5mm locking or non-locking) converge to target the best bone and maximize stability. Either option, when combined with the plate's proximal shaft screws, provides maximum fixation to promote fracture union.



All plates have a combination of compression slots and locking holes for maximum fixation

12-hole Locking Distal Clavicle Plate shown


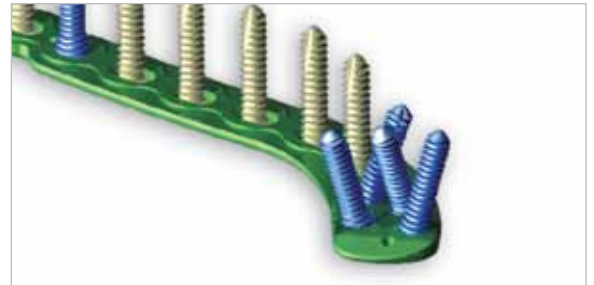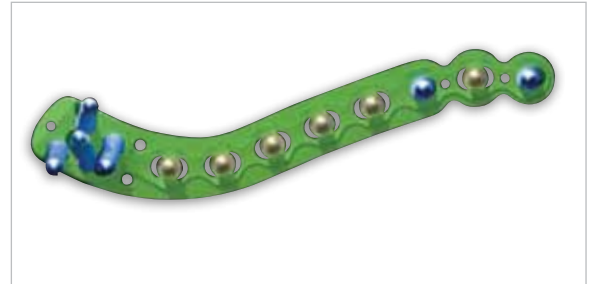
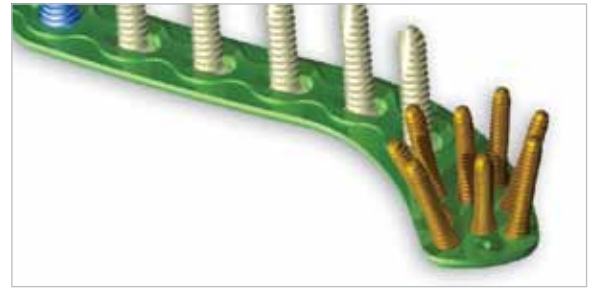
Precise Screw Placement

In order to improve fixation, Acumed designed the Locking Distal Clavicle Plates with diverging and converging screw constructs. The distal screw holes are angled to maximize pull-out strength and improve overall plate stability. In addition, the screw heads sit below the plate's surface minimizing soft tissue irritation. When combined with the proximal shaft screws, the plate provides maximum fixation to promote fracture union.

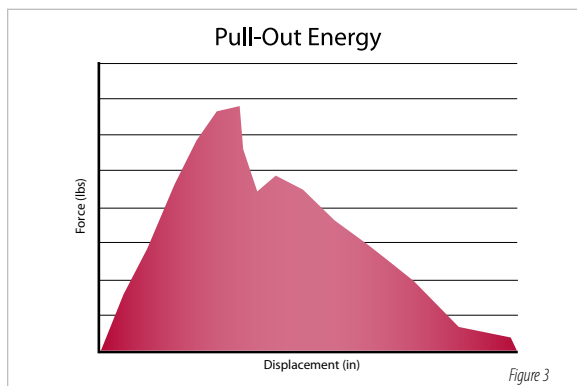
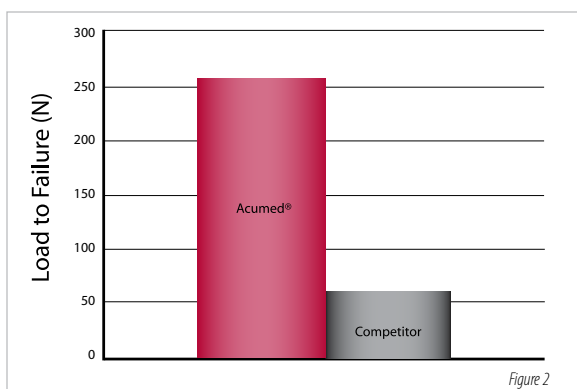
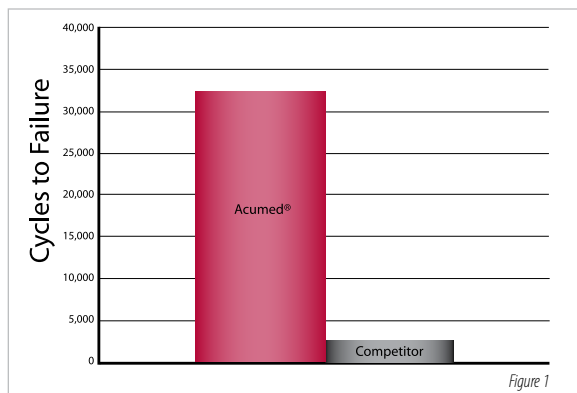
Acumed's 4-hole Locking Distal Clavicle Plate accepts 3.5mm unicortical locking and/or traditional bicortical non-locking screws. The patterned converging screw angle offers maximum pullout resistance to axial forces. If required, the surgeon also has the option to use 2.7mm unicortical and bicortical screws or 4.0mm cancellous screws depending upon the patient's bone quality.

The 8-hole Locking Distal Clavicle Plate utilizes 2.3mm screws positioned at diverging angles. This design ensures quality screw purchase and increased pull-out resistance in highly comminuted distal clavicle fractures. Fully threaded locking screws and non-toggling screws are available in lengths from 8mm to 20mm.

- 2.3mm gold fully threaded locking screws have the same pitch from tip to tail and are tapered under the head to facilitate insertion.
- 2.3mm silver non-toggling screws with enlarged tail end to minimize the toggle effect.
- 3.5mm blue proximal locking screws have the same pitch from tip to tail and are tapered under the head to facilitate insertion.
- 3.5mm silver non-locking cortical screws for bi-cortical proximal fixation.



Biomechanical Studies



A recent study evaluated the in-vitro biomechanical properties of an Acumed pre-contoured titanium clavicle plate to a Synthes 3.5mm limited contact dynamic compression (LCDC) plate. The results showed that “the Acumed clavicle plate and the 3.5mm LCDC plate did not differ in axial tension, axial compression, torsional tension, and torsional compression after plating.”⁵ The authors further noted that “the pre-contoured clavicle plate may afford several potential advantages. It has the anatomic shape of the natural clavicle and, with available right and left clavicle fittings, may decrease operative time. With a lower profile and round end, compared to the 3.5mm LCDC plate, greater cosmesis and patient tolerance of the plate are possible. The lower modules of elasticity of titanium compared to stainless steel may lead to less stress shielding.”⁵

In further testing, Oregon Health Sciences University (OHSU) Biomechanics Laboratory conducted mechanical testing comparing the strength of the 8-hole Acumed titanium Anterior Clavicle Plate to that of the Synthes Recon Plate made from 316L Stainless Steel. The tests showed that the Anterior Plates fractured at an average of 32,549 cycles (St Dev 5,202) versus 2,292 (St Dev 762) for Recon Plates in bending fatigue. (Figure 1) The proof load was shown to be 260N for Anterior Plates and 60N for Recon Plates. (Figure 2) The Acumed Anterior Clavicle Plate is more than 14 times stronger in bend fatigue and has a proof load more than 4 times that of the Synthes Recon Plate.⁶

A review of scientific literature illustrates that a Locking Compression Plate (LCP) is most susceptible to failure when the screws are loaded in a purely axial direction.⁷ A LCP plate applied to the superior aspect of the clavicle is at risk of this type of axial failure.⁸ This is particularly true in the lateral end of the clavicle because the weight of the arm can cause the clavicle to pull downward and sag away from the plate. In an effort to address this potential issue, a series of mechanical tests were performed and showed that angling screws has an impact on pull-out force. Using this data, Acumed designed the Locking Distal Clavicle Plates with diverging screw angles. Using a series of 2.3mm screws at diverging angles can significantly increase resistance to axial pull-out forces when compared to 3.5mm screws that are placed perpendicular to the plate.⁹ (Figure 3)

Shoulder Fracture Solutions

Acumed®'s Locking Scapula Plates are designed to provide excellent fixation for acute fractures, malunions and non-unions of the scapula. Designed in conjunction with William B. Geissler, M.D., Acumed's indication-specific plates allow surgeons to choose a construct based on their patients' needs. The pre-contoured design eliminates the need to bend the plates to match the patient's anatomy and better restores the functional angle of the shoulder joint. This design not only reduces OR time spent contouring a plate, but also minimizes soft tissue irritation for the patient. The pre-contoured plates help the surgeon reduce the fracture by acting as templates.



With the Polarus® PHP Locking Proximal Humeral Plate, Acumed has designed an advanced solution for repairing fractures of the proximal humerus. By incorporating a locking construct with an anatomical size and contour that best accommodates the patient, the Polarus PHP minimizes impingement and soft tissue irritation. To maximize stability in the humeral head, the proximal screws are precisely angled to capture and secure fracture fragments.



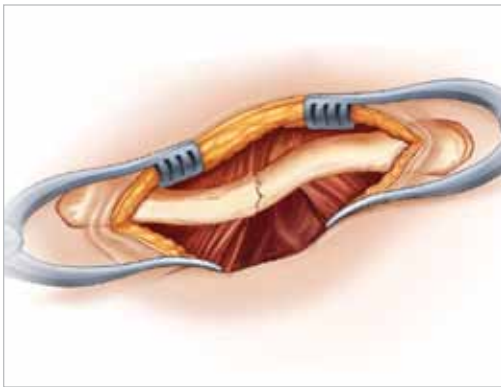
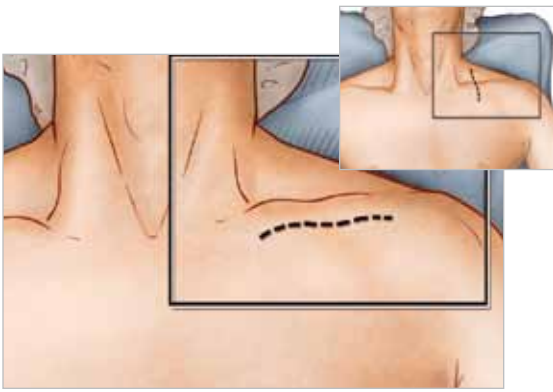
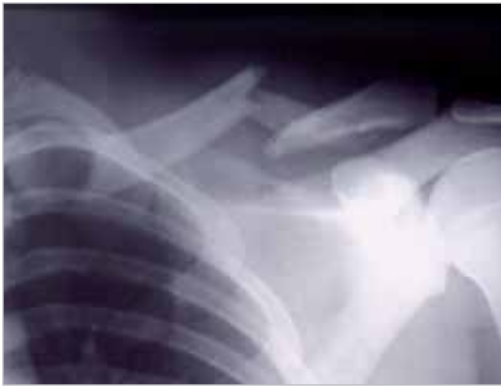The Polarus Locking Humeral Rod provides excellent fixation for 2-, and 3-part fractures of the proximal humerus. This 150mm cannulated intramedullary humeral rod features a tapered profile and patented spiral array of screws that provide multi-planar fixation and serve as a scaffold, restoring the proper anatomic alignment of the humerus through a percutaneous approach. With lengths offered from 200mm to 280mm, the Polarus Plus is the perfect solution for fractures of the proximal humerus that extend too far distal for the standard 150mm Locking Polarus Humeral Rod.



Hemiarthroplasty for proximal humeral fractures is a difficult and demanding surgery. With the Polarus Modular Shoulder System, both the implant and instrumentation are designed with features to address the common complications of shoulder hemiarthroplasty. Our unique implants feature a humeral head with medial and posterior offset; low-volume grit blasted body; long stems up to 280mm in length and interlocking distal screws. The targeting guide assembly addresses the difficulty of accurate implant positioning by controlling height, retroversion and accurate placement of the interlocking distal screws.



Locking Midshaft Clavicle Plate



STEP 1: Pre-operative Planning and Patient Positioning

After a thorough radiographic evaluation has been completed, the patient is placed in a beach chair position with the head rotated and tilted 5° to 10° degrees away from the operative side. A bolster is placed between the shoulder blades allowing the injured shoulder girdle to retract posteriorly. This will help facilitate reduction by bringing the clavicle anterior to restore length and improve exposure. The patient's involved upper extremity is prepped and draped in a sterile fashion allowing the arm to be manipulated to help further reduce the fracture if required.

Tip: Radiographic evaluation begins with an anteroposterior (AP) view to evaluate the acromioclavicular (AC), coracoclavicular (CC) and sternoclavicular (SC) joints. If thoracic structures obstruct the image, a 20° to 60° cephalad-tilted view may be utilized. For displaced fracture fragments, especially in the event of a vertically oriented butterfly fragment, a 45° AP oblique view may be helpful. If subluxation or dislocation of the medial clavicle or the SC joint is suspected, capture a 40° cephalic tilt view (serendipity view) of the SC joint.¹⁰ If the decision on operative treatment is influenced by shortening of the clavicle, a Posteroanterior (PA) 15° caudal x-ray more is suggested to assess the difference compared to the non-injured side.¹¹

STEP 2: Exposure

Surgeons may choose one of two incisions: Option one, a 6cm transverse (medial to lateral) infraclavicular incision is made parallel to the long axis of the clavicle so that the scar does not lie over the plate. This approach provides convenient, unlimited access to the entire length of the bone. Option two, an incision along Langer's Lines running perpendicular to the long axis. This provides better cosmetic results and less damage to the supraclavicular cutaneous nerves.

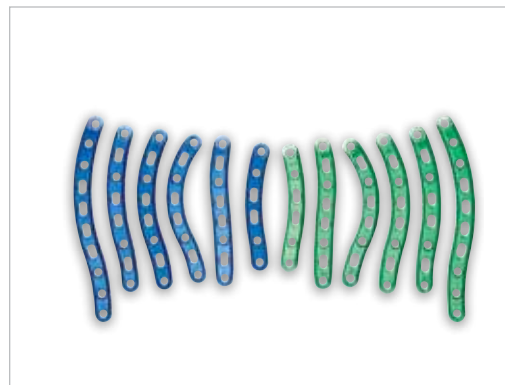
The subcutaneous fat is incised together with any fibers of the platysma. Identifying and protecting branches of the supraclavicular nerves preserves cutaneous sensation inferior to the incision. The pectoralis fascia is divided in line with the incision and elevated with electrocautery to create thick flaps that can be closed over the plate at the end of the procedure. It is important to keep soft tissue attachments to the butterfly fragments in an attempt to maintain vascularity.

STEP 3: Plate Selection

Reduce the fracture by placing two reduction clamps on the medial and distal fragments. The medial fragment is usually proximal in relation to the distal fragment. Distract, elevate and derotate the distal fragment to obtain reduction. The appropriately sized left or right midshaft clavicle plate is selected from the different lengths and curvatures in the system. Place the two middle slots over the fracture, ideally leaving three locking and/or non-locking holes both medial and distal to the fracture fragments; however, the plate may be slid medially or laterally for the most ideal location. In cases of non-union or malunion, the curve of the plate may assist in anatomic reduction of the clavicle, reducing strain on the SC and AC joints.

Tip: Prior to placement of the plate, lag screw fixation across the major fracture fragments may be performed for neutralization or axial compression. To reduce and fix the bigger intermediate fragments to one or both main fragments before applying the plate, drill the near cortex with the 3.5mm drill (MS-DC35). The 3.5mm drill sleeve (MS-SS35) is then inserted and the far cortex is drilled using a 2.8mm drill (MS-DC28). It is important to preserve the soft tissue attachments.

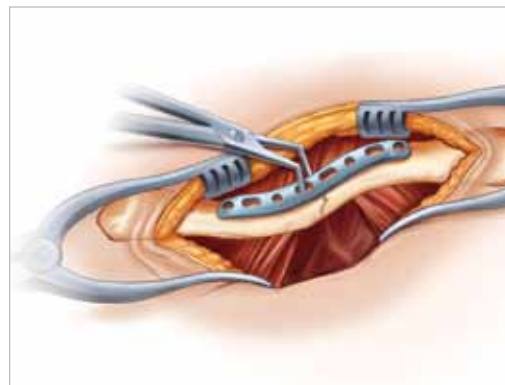
Tip: Usually the larger plates are ideal for most males, the medium plates for smaller males and most females, and the smallest plates for the smallest patients.



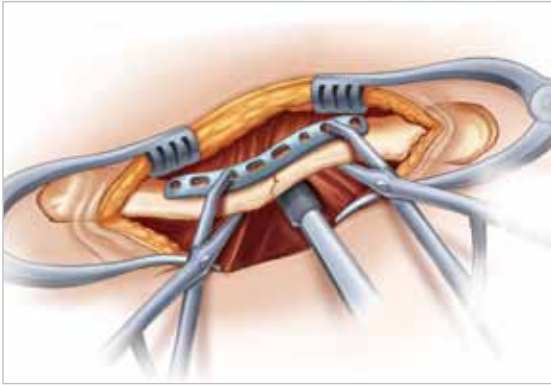
STEP 4: Plate Placement

Once the plate's ideal positioning has been selected, it is provisionally stabilized to the clavicle with plate tacks (PL-PTACK) or bone clamps (PL-CL04). Ideally the plate should be applied in compression mode to reduce the risk of delayed union or non-union. The plate may be applied to one of the major fracture fragments and used as a tool to reduce other major fragments to this bone-plate construct. Take care to ensure that the intervening fragments are not stripped. Preservation of soft tissue attachments helps ensure that the length and rotation of the clavicle are correct.

Tip: The plate may be rotated 180° for a more anatomical fit on fractures that are more lateral than the central 1/3. A plate of the opposite dexterity may be used if the patient's anatomy requires a different curvature than that provided with the correct-sided plate.



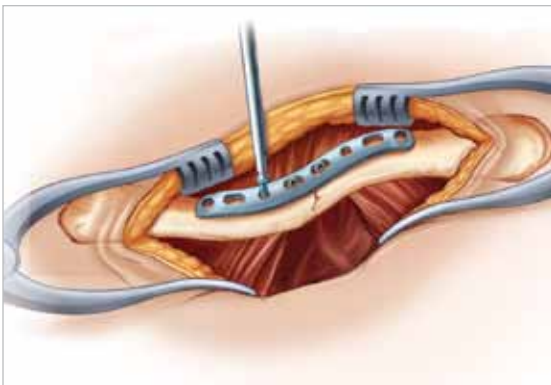
Locking Midshaft Clavicle Plate



STEP 5: Non-Locking Screw Insertion

Non-locking screws may be placed either unicortical or bicortical. If bicortical screws are used, it is important not to over-penetrate the inferior cortex and potentially risk neurovascular injury. A curved retractor (PL-CL03) or other means of protection should be placed under the inferior surface of the clavicle to protect the neurovascular structures from over-penetration of the drill bit. For early stability, the first two screws placed should be medial and lateral to the fracture site. Although 3.5mm cortical screws (CO-3XX0) are recommended, optional 2.7mm cortical (CO-27XX) and 4.0mm cancellous (CA-4XX0) screws are available upon request. Assemble the driver handle (MS-3200 or MS-1210) to the driver tip (HPC-0025 or HT-2502). Using the appropriate drill size (MS-DC28 or 80-0318) and the offset drill guide (PL-2095), drill, measure for depth (MS-9022) and place the screws into the slots with the assembled driver. Once the two screws are installed, the plate tacks or bone clamps holding the plate to the clavicle may be removed.

Tip: The drill (MS-DC28 or 80-0318) will need to be replaced if it comes in contact with the retractor.



STEP 6: Locking Screw Insertion

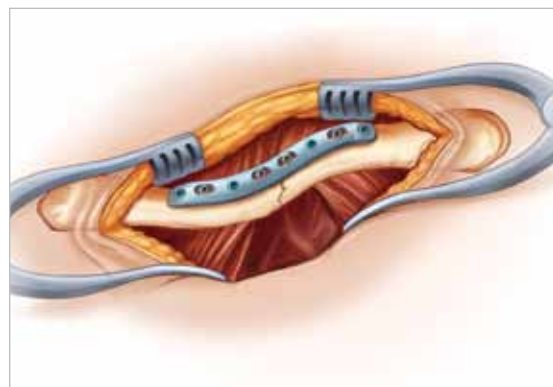
Using the locking drill guide (MS-LDG35) and the 2.8mm drill (MS-DC28), place the 3.5mm locking screws (COL-3XX0) into the threaded holes so that there are at least three screws (if possible) on each side of the fracture.

Tip: The bolster may be temporarily removed or the long driver tip (HT-2502) may be used if the patient's head is in the way during drilling and insertion of screws. Once the medial screws are placed, the bolster may be replaced under the patient's head. Tapping (MS-LTT35 or MS-LTT27) is recommended for patients with dense bone. The drill guide must be removed prior to tapping.

Tip: Depending on the degree of comminution, demineralized bone matrix, iliac crest autograft or allograft bone chips may be used to fill areas devoid of bone.¹² In hypertrophic non-unions, callus from the non-union site may be sufficient to provide graft material. If local material seems insufficient, demineralized bone matrix may be as effective as bone graft in achieving union when osteoconductive material is needed.¹³

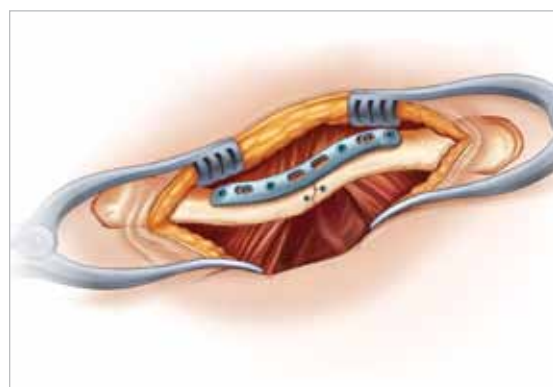
STEP 7: Final Plate and Screw Position

An intraoperative radiograph is recommended to check the position of the screws and the final reduction of the fracture. If the surgeon feels the bone quality of the lateral fragment is poor, sutures may be passed from medial to lateral around the coracoid process and the plate to take stress off of the lateral fixation. After radiographic evaluation and thorough irrigation, the clavipectoral fascia is closed over the clavicle and the plate, followed by closure of the subcutaneous tissue and musculature in separate layers. Finally, close the skin by using interrupted absorbable sutures with a subcuticular stitch and dress the wound.



Post-op Protocol

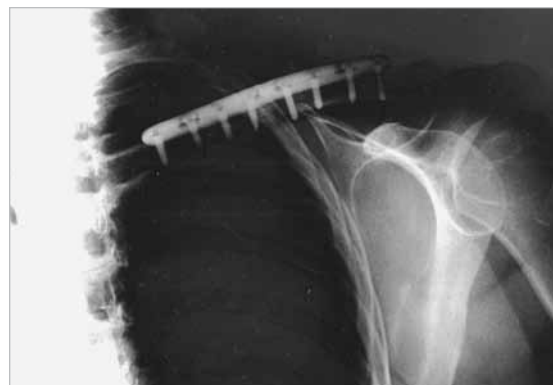For the first four weeks, the patient is placed in either an arm sling or an abduction pillow which tends to bring the arm up and the clavicle down, unloading the AC joint.¹⁴ Passive range of motion exercises are initiated for the first four weeks. Exercises may include pendulum, Codman, isometric bicep, and elbow and wrist motion. It should be emphasized to patients that they must avoid any activity involving heavy lifting, pushing or pulling. Depending on the amount of comminution and the stability of fixation, active assisted exercise is started from four to six weeks, and active strengthening is initiated at six to eight weeks post-operatively, once healing is seen radiographically. A full return to activities is permitted once healing has occurred.



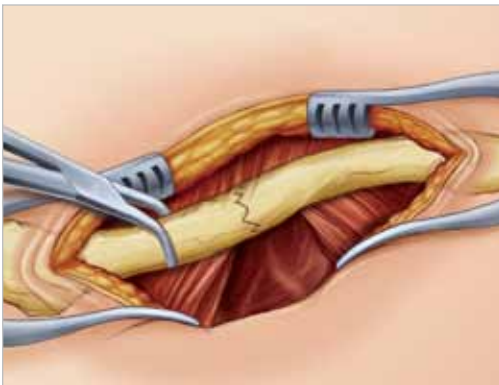
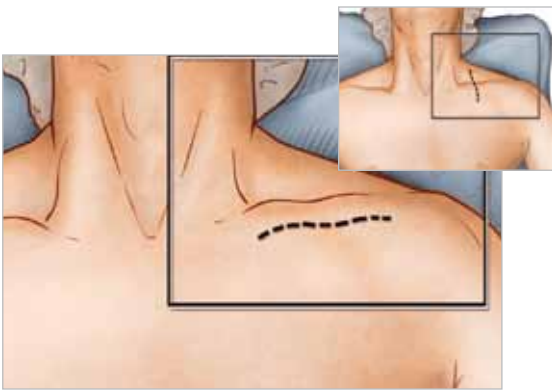
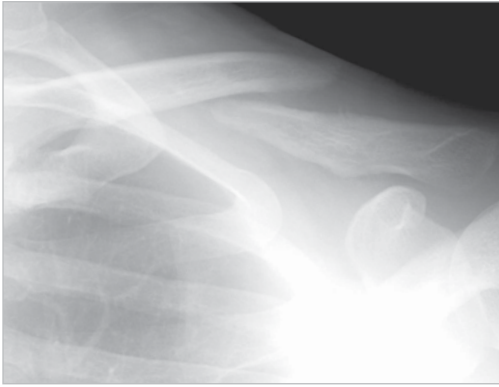Tip: Due to risk of refracture, implant removal is generally not recommended before two years after ORIF.

Contraindications

Pre-operative planning and patient selection are crucial. Patients at high risk for multiple falls, alcohol abuse or non-compliance may have early mechanical failure of the fixation and are not candidates for this procedure. Additional contraindications include: active infection in the operative area; prior soft tissue irradiation in the operative area; burns over the clavicular area; debilitating medical conditions; an elderly patient with a sedentary lifestyle. Patients who are unable or unwilling to participate in a post-operative rehabilitation program are not candidates for surgical intervention.¹⁵



Locking Anterior Clavicle Plate



STEP 1: Pre-Operative Planning and Patient Positioning

After a thorough radiographic evaluation has been completed, the patient is placed in a beach chair position with the head rotated and tilted 5° to 10° away from the operative side. A bolster is placed between the shoulder blades allowing the injured shoulder girdle to retract posteriorly. This will help facilitate reduction by bringing the clavicle anterior to restore length and improve exposure. The patient's involved upper extremity is prepped and draped in a sterile fashion allowing the arm to be manipulated to help further reduce the fracture if required.

Tip: Radiographic evaluation begins with an anteroposterior (AP) view to evaluate the acromioclavicular (AC), coracoclavicular (CC) and sternoclavicular (SC) joints. If thoracic structures obstruct the image, a 20° to 60° cephalad-tilted view may be utilized. For displaced fracture fragments, especially in the event of a vertically oriented butterfly fragment, a 45° AP oblique view may be helpful. If subluxation or dislocation of the medial clavicle or the SC joint is suspected, capture a 40° cephalic tilt view (serendipity view) of the SC joint.⁹ If the decision on operative treatment is influenced by shortening of the clavicle, a Posteroanterior (PA) 15° caudal x-ray more is suggested to reliably assess the difference compared to the non-injured side.¹⁰

STEP 2: Exposure

Surgeons may choose one of two incisions: Option one, a 6cm transverse (medial to lateral) infraclavicular incision is made parallel to the long axis of the clavicle so that the scar does not lie over the plate. This approach provides convenient, unlimited access to the entire length of the bone. Option two, an incision along Langer's Lines running perpendicular to the long axis. This provides better cosmetic results and less damage to the supraclavicular cutaneous nerves.

The lateral platysma is released, and the supraclavicular nerves are identified traversing the anterior aspect of the clavicle and spared. The clavipectoral fascia is then incised along its attachment to the anterior clavicle and carefully elevated in an inferior direction. Dissection is first performed along the medial fragment which is usually flexed up away from the vital intraclavicular structures. In the case of an acute fracture, minimal soft tissue dissection is performed at the fracture site. In cases of non-union, fibrous tissue is debrided if necessary and the fracture ends drilled to open the intramedullary canal.¹⁶ It is important to keep soft tissue attachments to the butterfly fragments in an attempt to maintain vascularity. The fracture is reduced.

STEP 3: Plate Selections

Select the appropriately sized Locking Anterior Clavicle Plate from the different lengths and curvatures provided. The two middle slots may be placed over the fracture, ideally leaving three locking and/or non-locking holes both proximal and distal to the fracture fragments; however, the plate can be slid medially or laterally for the most ideal location. The curve of the plate can assist in anatomic reduction of the clavicle.

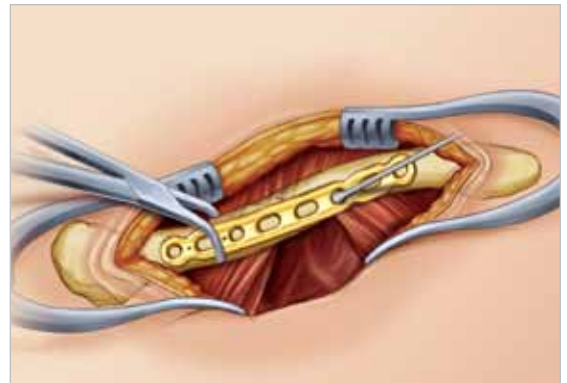
Tip: When an oblique fracture line is present, a lag screw either through the plate or directly into the bone at roughly a 90° angle to the fracture may be used depending upon fracture configuration. Lag screws utilized in this fashion greatly increases the strength of the construct.¹⁷ After the near cortex is drilled with the 3.5mm drill (MS-DC35), the 3.5mm drill sleeve (MS-SS35) is inserted and the far cortex is drilled with a 2.8mm drill (MS-DC28). Plate benders (PL-2045) are available in the event that plate contouring is required to achieve an exact fit to the clavicle.



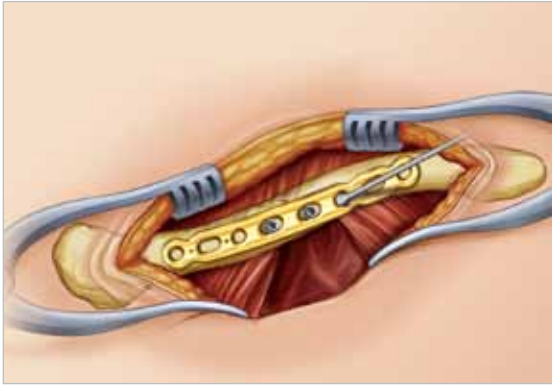
STEP 4: Plate Placement

Once the plate's ideal positioning has been selected, it is provisionally stabilized to the clavicle with plate tacks (PL-PTACK) or bone clamps (PL-CL04). The non-locking screws may be placed either unicortical or bicortical. If bicortical screws are used, it is important not to over-penetrates the posterior cortex and potentially risk neurovascular injury. A curved retractor (PL-CL03) is provided as a means of protecting the surrounding neurovascular structures.

Tip: The plate may be rotated 180° for a more anatomical fit.



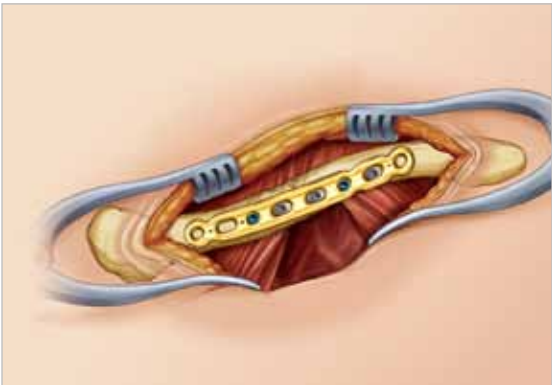
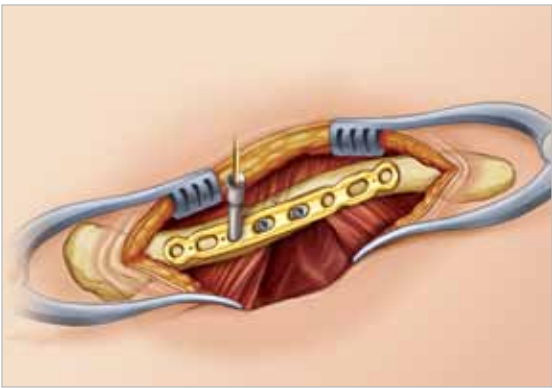
Locking Anterior Clavicle Plate



STEP 5: Non-Locking Screw Insertion

Non-locking screws may be placed either unicortical or bicortical. If bicortical screws are used, it is important not to over-penetrate the posterior cortex and potentially risk injury to the brachial plexus. A curved retractor (PL-CL03) or other means of protection should be used to protect from over-penetration of the drill bit. For early stability, the first two screws placed should be medial and lateral to the fracture site. Although 3.5mm cortical screws (CO-3XX0) are recommended, optional 2.7mm cortical (CO-27XX) and 4.0mm cancellous (CA-4XX0) screws are available upon request. Assemble the driver handle (MS-3200 or MS-1210) to the driver tip (HPC-0025 or HT-2502). Using the appropriate drill size (MS-DC28 or 80-0318) and the offset drill guide (PL-2095), drill, measure for depth (MS-9022) and place the screws into the slots with the assembled driver. Once the two screws are installed, the plate tacks or bone clamps holding the plate to the clavicle may be removed.

Tip: The drill (MS-DC28 or 80-0318) will need to be replaced if it comes in contact with the retractor.



STEP 6: Locking Screw Insertion

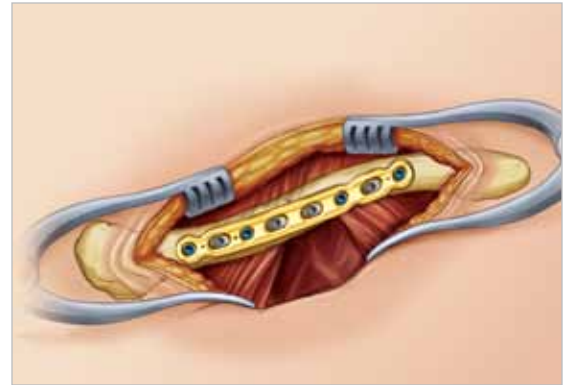
Using the locking drill guide (MS-LDG35) and the 2.8mm drill (MS-DC28), place the 3.5mm locking screws (COL-3XX0) into the threaded holes so that there are at least three screws (if possible) on each side of the fracture.

Tip: Tapping (MS-LTT35 or MS-LTT27) is recommended for patients with dense bone. The drill guide must be removed prior to tapping.

Tip: Depending on the degree of comminution, demineralized bone matrix, iliac crest autograft, or allograft bone chips may be used to fill areas devoid of bone.¹² In hypertrophic non-unions, callus from the non-union site may be sufficient to provide graft material.

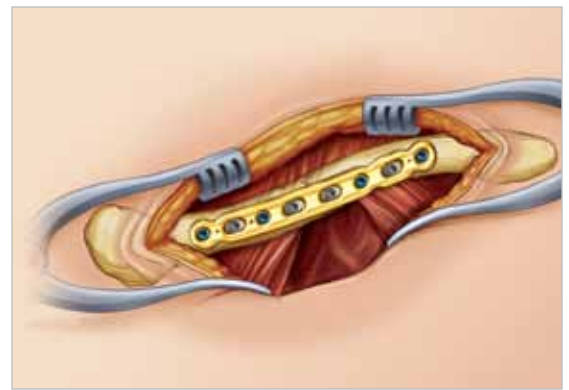
STEP 7: Final Plate and Screw Position

An intraoperative radiograph is recommended to check the position of the screws and the final reduction of the fracture. If the surgeon feels the bone quality of the lateral fragment is poor, sutures may be passed from medial to lateral around the coracoid process and the plate to take stress off of the lateral fixation. After radiographic evaluation and thorough irrigation, the clavipectoral fascia is closed over the clavicle and the plate, followed by closure of the subcutaneous tissue and musculature in separate layers. Finally, close the skin by using interrupted absorbable sutures with a subcuticular stitch and dress the wound.



Post-op Protocol

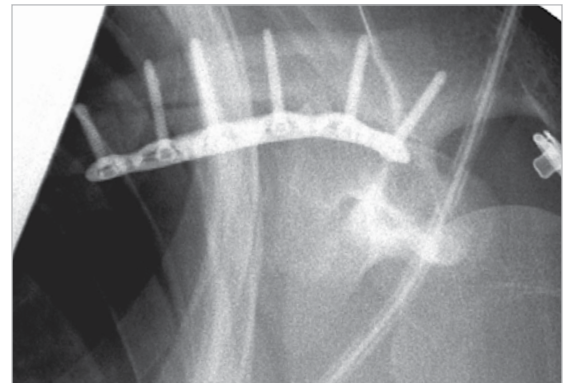
For the first four weeks, the patient is placed in either an arm sling or an abduction pillow which tends to bring the arm up and the clavicle down, unloading the AC joint.¹⁴ Passive range of motion exercises are initiated from the first four weeks. Exercises may include pendulum, Codman, isometric bicep, and elbow and wrist motion. It should be emphasized to patients that they must avoid any activity involving heavy lifting, pushing or pulling. Depending on the amount of comminution and the stability of fixation, active assisted exercise is started from four to six weeks, and active strengthening is initiated at six to eight weeks post-operatively, once healing is seen radiographically. Full return to activities is permitted once healing has occurred.



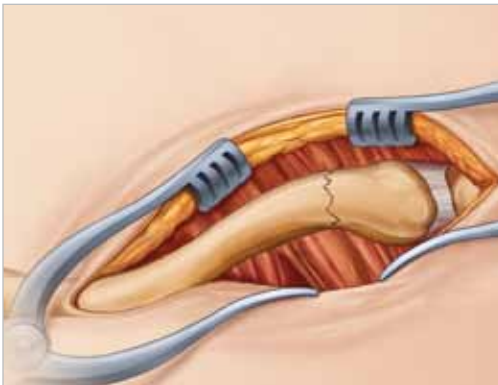
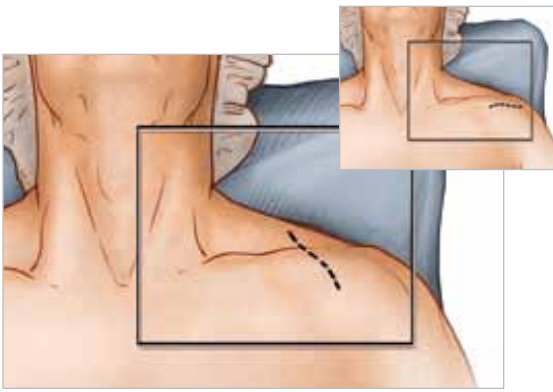
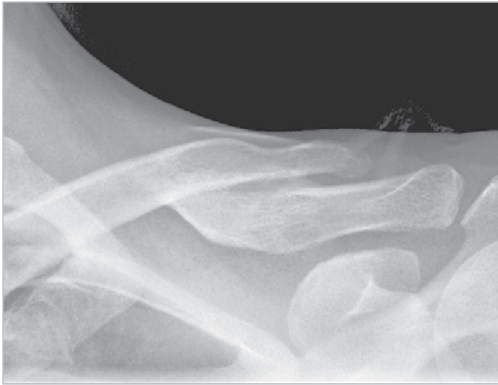Tip: Due to risk of refracture, implant removal is generally not recommended before two years after ORIF.

Contraindications

Pre-operative planning and patient selection are crucial. Patients at high risk for multiple falls, alcohol abuse or non-compliance may have early mechanical failure of the fixation and are not candidates for this procedure. Additional contraindications include: active infection in the operative area; prior soft tissue irradiation in the operative area; burns over the clavicular area; debilitating medical conditions; an elderly patient with a sedentary lifestyle. Patients who are unable or unwilling to participate in a post-operative rehabilitation program are not candidates for surgical intervention.¹⁵



Locking Distal Clavicle Plate



STEP 1: Pre-operative Planning and Patient Positioning

After a thorough radiographic evaluation has been completed, the patient is placed in a beach chair position with the head rotated and tilted 5° to 10° away from the operative side. A bolster is placed between the shoulder blades allowing the injured shoulder girdle to retract posteriorly. This helps facilitate reduction by bringing the clavicle anterior to restore length and improve exposure. The patient's involved upper extremity is prepped and draped in a sterile fashion allowing the arm to be manipulated to help further reduce the fracture if required.

Tip: After axial trauma to the shoulder, it is important to complete a full clinical workup as this injury is not only a bony injury, but usually a soft tissue event involving the disruption of the coracoclavicular (CC) ligaments and acromioclavicular (AC) joint.¹⁸ Thus, examination of the AC and CC ligaments is important in the success of the repair. Step 1 of the Locking Midshaft Clavicle Plate surgical technique provides a complete profile of options for radiographic evaluation. It is important to note that an AP radiograph can underestimate the displacement of the distal clavicle. If AC joint widening is visualized on the AP view, an axillary radiograph should be taken to determine if an AC separation is present.¹⁹


STEP 2: Exposure

Approximately a 6cm transverse (medial to lateral) incision is made inferior to the distal clavicle and AC joint. The incision is usually placed midway between the medial/lateral migration of the proximal fragments. Dissection is carried down to the fascia and the skin flaps are elevated. The cutaneous nerves are protected. The trapezial-deltoid musculature is then subperiosteally elevated off the bone fragments avoiding the infraclavicular nerve branches below the clavicle. It is important to keep soft tissue attachments to the butterfly fragments in an attempt to maintain vascularity. The fracture is reduced.

STEP 3: Plate Selection

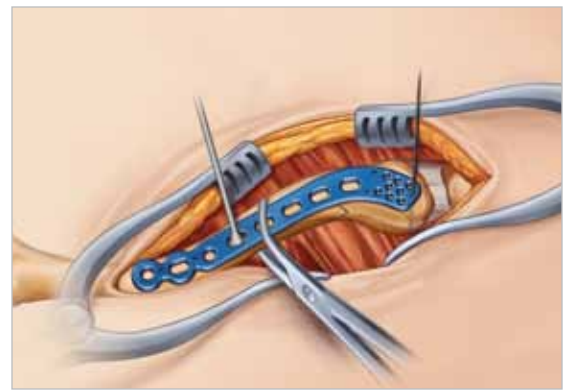
Select the appropriately sized Locking Distal Clavicle Plate from the different lengths and curvatures in the system. The curve of the plate can assist in anatomic reduction of the clavicle, reducing strain on the SC and AC joints.

Tip: Lag screws may be used for interfragmentary fixation. Many Type IIB clavicle fractures have a horizontal cleavage fracture that extends into the AC joint, which may be fixed in this manner.²⁰ Lifting the arm superiorly helps reduce the AC joint. After the near cortex is drilled with the 3.5mm drill (MS-DC35), the 2.3/3.5mm drill sleeve (MS-SS23/MS-SS35) is inserted and the far cortex is drilled with a 2.8mm drill (MS-DC28).



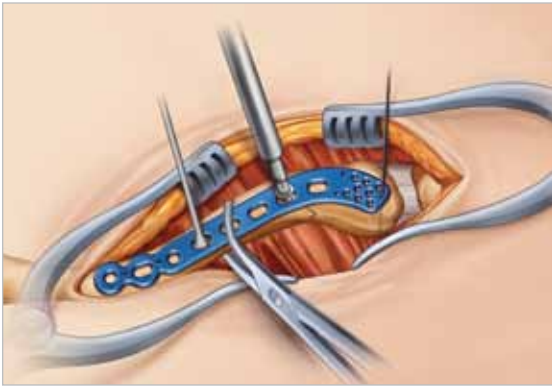
STEP 4: Plate Placement

Once the plate's ideal positioning has been selected, it is provisionally stabilized to the clavicle with plate tacks (PL-PTACK) or bone clamps (PL-CL04). The lateral-most K-wire hole of each Locking Distal Clavicle Plate affords the opportunity to, under radiographic evaluation, verify that the placement of the screws will not protrude into the AC joint. The non-locking screws may be placed either unicortical or bicortical. If bicortical screws are used, it is important not to over-penetrate the inferior cortex and potentially risk neurovascular injury. A curved retractor (PL-CL03) or other means of protection should be placed under the inferior surface of the clavicle to protect the neurovascular structures from over-penetration of the drill bit.



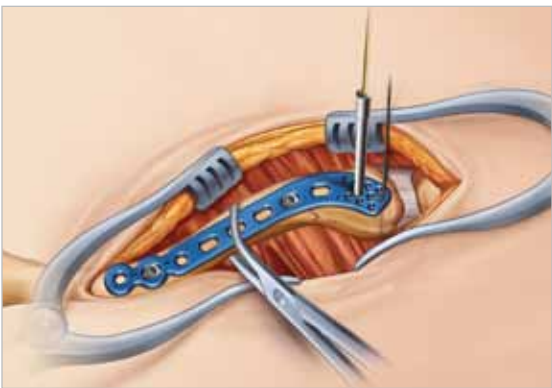
*Surgical technique from here on will highlight a plate utilizing eight 2.3mm screws.

Locking Distal Clavicle Plate



STEP 5: Non-Locking Screw Insertion

For early stability, the first two screws placed should be medial and lateral to the fracture site. Based on the selected plate, 2.3mm non-toggling (CO-N23XX) and 3.5mm cortical screws (CO-3XX0) are recommended, with optional 2.7mm cortical screws (CO-27XX) and 4.0mm cancellous (CA-4XX0) screws available upon request. Assemble the driver handle (MS-3200 or MS-1210) to the driver tip (HPC-0025 or HT-2502). Using the appropriate drill size (MS-DC28 or 80-0318) and the offset drill guide (PL-2095), drill, measure for depth (MS-9022) and place the screws into the slots with the assembled driver. Once the two screws are installed, the plate tacks and bone clamps holding the plate to the clavicle may be removed.

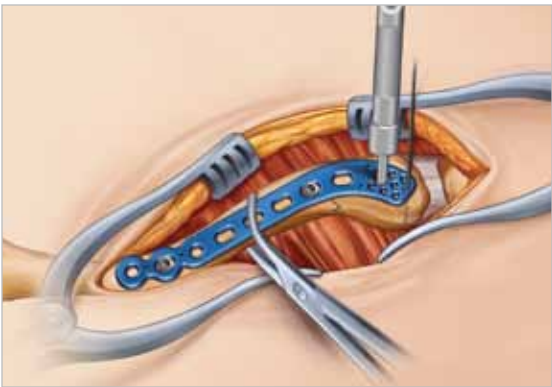


STEP 6: Locking Screw Insertion

For the midshaft portion, use the locking drill guide (MS-LDG35) and the 2.8mm drill (MS-DC28) to place the 3.5mm locking screws (COL-3XX0). For 3.5mm or 2.7mm screws in the distal portion, use the locking drill guide ((MS-LDG35) and the 2.8mm drill (MS-DC28). To place the 2.3mm locking screws (CO-T23XX/CO-N23XX) into the threaded holes use the 1.5mm hex driver tip (HPC-0015) with the driver handle (MS-2210). The screws holes will be drilled using the (MS-LDG23) and the 2.0mm drill (80-0318).

Tip: Tapping (MS-LTT35 or MS-LTT27) is recommended for patients with dense bone. The drill guide (MS-LDG35 or MS-LDG23) must be removed prior to tapping.

Tip: A minimum of six, 2.3mm threaded locking or non-toggling screws in the distal portion is recommended.



STEP 7: Final Plate & Screw Placement

An intraoperative radiograph is recommended to check the position of the screws and the final reduction of the fracture. If the surgeon feels the bone quality of the lateral fragment is poor, sutures may be passed from medial to lateral around the coracoid process and the plate to take stress off of the lateral fixation. After radiographic evaluation and routine irrigation, the trapezial-deltoid fascia is closed over the clavicle and AC joint, followed by closure of the subcutaneous tissue and skin. The wound is dressed and the arm placed in an abduction pillow which tends to bring the arm up and the clavicle down, unloading the AC joint.

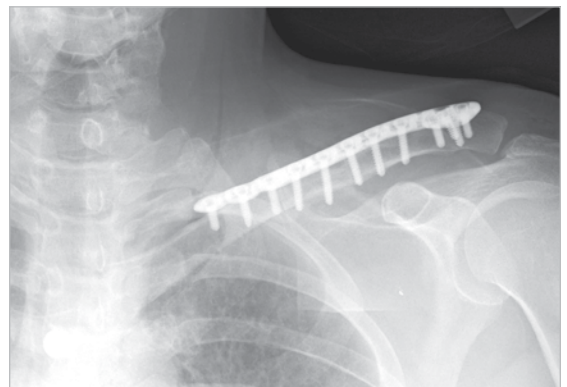
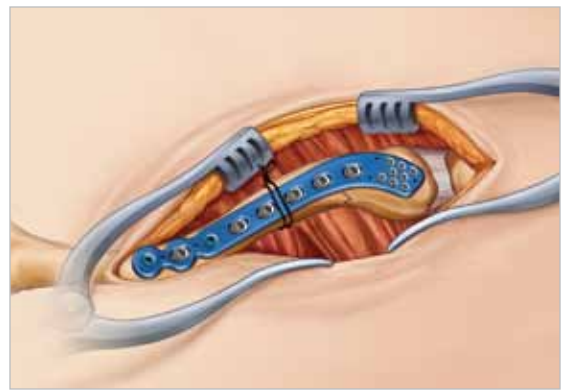
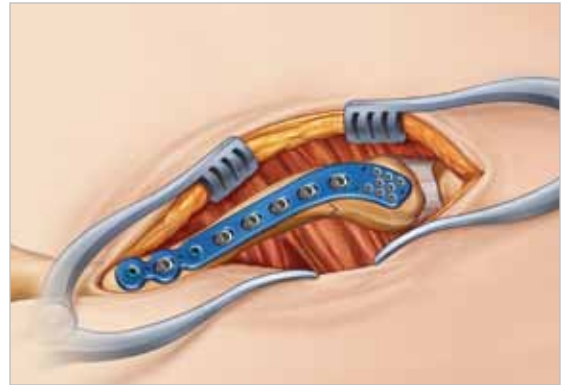
Post-op Protocol

For the first four weeks, the patient is placed in either an arm sling or an abduction pillow which tends to bring the arm up and the clavicle down, unloading the AC joint. Passive range of motion exercises are initiated from the first four weeks. Exercises may include pendulum, Codman, isometric bicep, and elbow and wrist motion. It should be emphasized to patients that they must avoid any activity involving heavy lifting, pushing or pulling. Depending on the amount of comminution and the stability of fixation, active assisted exercise is started from four to six weeks, and active strengthening is initiated at six to eight weeks post-operatively, once healing is seen radiographically. Full return to activities is permitted once healing has occurred.

Tip: Due to risk of refracture, implant removal is generally not recommended before two years after ORIF.

Contraindications

Pre-operative planning and patient selection are crucial. Patients at high risk for multiple falls, alcohol abuse or non-compliance may have early mechanical failure of the fixation and are not candidates for this procedure. Additional contraindications include: active infection in the operative area; prior soft tissue irradiation in the operative area; burns over the clavicular area; debilitating medical conditions; an elderly patient with a sedentary lifestyle. Patients who are unable or unwilling to participate in a post-operative rehabilitation program are not candidates for surgical intervention.



Ordering Information

Locking Midshaft Clavicle Plates

Locking Clavicle Plate, 10 Hole, Large, Left	PL-CL10LL
Locking Clavicle Plate, 10 Hole, Large, Right	PL-CL10LR
Locking Clavicle Plate, 6 Hole, Large, Left	PL-CL6SL
Locking Clavicle Plate, 6 Hole, Large, Right	PL-CL6SR
Locking Clavicle Plate, 8 Hole, Large, Left	PL-CL8LL
Locking Clavicle Plate, 8 Hole, Large, Right	PL-CL8LR
Locking Clavicle Plate, 8 Hole, Medium, Left	PL-CL8ML
Locking Clavicle Plate, 8 Hole, Medium, Right	PL-CL8MR
Locking Clavicle Plate, 8 Hole, Small, Left	PL-CL8SL
Locking Clavicle Plate, 8 Hole, Small, Right	PL-CL8SR
Locking Clavicle Plate, 8 Hole, Straight, Left	70-0096
Locking Clavicle Plate, 8 Hole, Straight, Right	70-0095

Locking Distal Clavicle Plates

Distal Clavicle Plate 3.5mm 12 Hole Right	70-0111
Distal Clavicle Plate 3.5mm 12 Hole Left	70-0112
Distal Clavicle Plate 3.5mm 9 Hole Right	70-0116
Distal Clavicle Plate 3.5mm 9 Hole Left	70-0117
Distal Clavicle Plate 2.3mm 16 Hole Right	70-0123
Distal Clavicle Plate 2.3mm 16 Hole Left	70-0124
Distal Clavicle Plate 2.3mm 13 Hole Right	70-0125
Distal Clavicle Plate 2.3mm 13 Hole Left	70-0126

Locking Anterior Clavicle Plates

8 Hole Lateral Anterior Clavicle Plate	70-0118
8 Hole Medial Anterior Clavicle Plate	70-0119
6 Hole Lateral Anterior Clavicle Plate	70-0122
6 Hole Medial Anterior Clavicle Plate	70-0120
10 Hole Anterior Clavicle Plate	70-0121

2.3mm Threaded Locking Screws

2.3mm x 8mm Locking Cortical Screw	CO-T2308
2.3mm x 10mm Locking Cortical Screw	CO-T2310
2.3mm x 12mm Locking Cortical Screw	CO-T2312
2.3mm x 14mm Locking Cortical Screw	CO-T2314
2.3mm x 16mm Locking Cortical Screw	CO-T2316

2.3mm Threaded Locking Screws (cont.)

2.3mm x 18mm Locking Cortical Screw	CO-T2318
2.3mm x 20mm Locking Cortical Screw	CO-T2320

3.5mm Non-Locking Cortical Screws

3.5mm X 8mm Cortical Screw	CO-3080
3.5mm X 10mm Cortical Screw	CO-3100
3.5mm X 12mm Cortical Screw	CO-3120
3.5mm X 14mm Cortical Screw	CO-3140
3.5mm X 16mm Cortical Screw	CO-3160
3.5mm X 18mm Cortical Screw	CO-3180
3.5mm X 20mm Cortical Screw	CO-3200
3.5mm X 22mm Cortical Screw	CO-3220
3.5mm X 24mm Cortical Screw	CO-3240
3.5mm X 26mm Cortical Screw	CO-3260

2.7mm Non-Locking Cortical Screws

2.7mm X 8mm Cortical Screw	CO-2708
2.7mm X 10mm Cortical Screw	CO-2710
2.7mm X 12mm Cortical Screw	CO-2712
2.7mm X 14mm Cortical Screw	CO-2714
2.7mm X 16mm Cortical Screw	CO-2716
2.7mm X 18mm Cortical Screw	CO-2718
2.7mm X 20mm Cortical Screw	CO-2720
2.7mm X 22mm Cortical Screw	CO-2722
2.7mm X 24mm Cortical Screw	CO-2724
2.7mm X 26mm Cortical Screw	CO-2726

2.3mm Threaded Non-Toggling Screws

2.3mm x 8mm Non-Toggling Cortical Screw	CO-N2308
2.3mm x 10mm Non-Toggling Cortical Screw	CO-N2310
2.3mm x 12mm Non-Toggling Cortical Screw	CO-N2312
2.3mm x 14mm Non-Toggling Cortical Screw	CO-N2314
2.3mm x 16mm Non-Toggling Cortical Screw	CO-N2316
2.3mm x 18mm Non-Toggling Cortical Screw	CO-N2318
2.3mm x 20mm Non-Toggling Cortical Screw	CO-N2320

Ordering Information

3.5mm Locking Cortical Screws

3.5mm X 8mm Locking Cortical Screw	COL-3080
3.5mm X 10mm Locking Cortical Screw	COL-3100
3.5mm X 12mm Locking Cortical Screw	COL-3120
3.5mm X 14mm Locking Cortical Screw	COL-3140
3.5mm X 16mm Locking Cortical Screw	COL-3160
3.5mm X 18mm Locking Cortical Screw	COL-3180
3.5mm X 20mm Locking Cortical Screw	COL-3200
3.5mm X 22mm Locking Cortical Screw	COL-3220
3.5mm X 24mm Locking Cortical Screw	COL-3240
3.5mm X 26mm Locking Cortical Screw	COL-3260

4.0mm Cancellous Screws

4.0mm X 12mm Cancellous Screw	CA-4120
4.0mm X 14mm Cancellous Screw	CA-4140
4.0mm X 16mm Cancellous Screw	CA-4160
4.0mm X 18mm Cancellous Screw	CA-4180
4.0mm X 20mm Cancellous Screw	CA-4200
4.0mm X 22mm Cancellous Screw	CA-4220
4.0mm X 24mm Cancellous Screw	CA-4240
4.0mm X 26mm Cancellous Screw	CA-4260

Distal Clavicle Instrumentation

Driver Handle	MS-2210
1.5mm Hex Driver Tip (small shaft)	HPC-0015
2.3mm Screw Sleeve	MS-SS23
Locking Drill Guide/Depth Gage	MS-LDG23
2.0mm Quick Coupler Surgibit Drill	80-0318
Screw Caddy	80-0348

Universal Tray

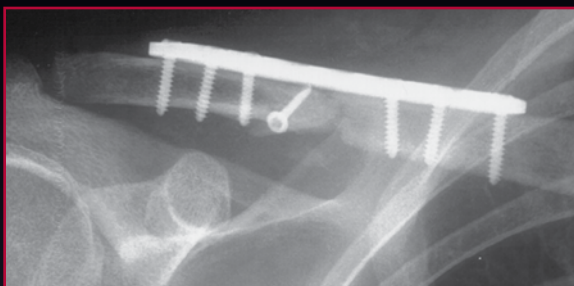
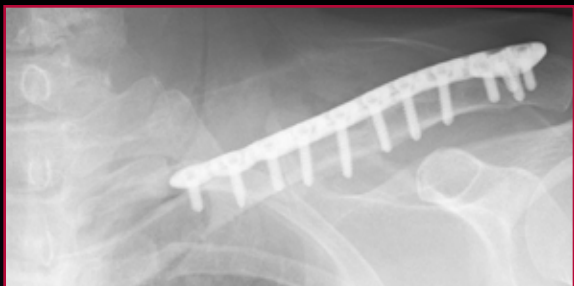
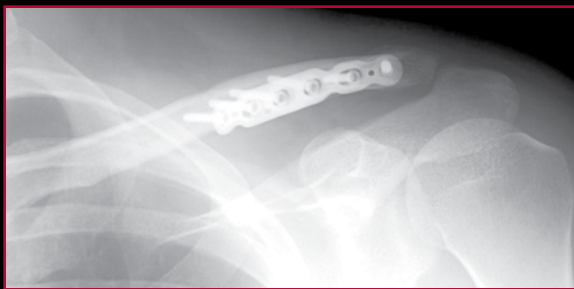Universal Tray Large Assembly	80-0341
Universal Tray Standard Instrument 1 Insert	80-0344
Universal Tray Standard Instrument 2 Insert	80-0345
Universal Tray Utility Insert	80-0347
Universal Tray Superior Clavicle Insert Assembly	80-0299
Universal Tray Clavicle Plate Insert Assembly	80-0307

Ancillary Tray

Small Quick Coupler Handle	MS-1210
Reduction Forceps With Teeth	PL-CL04
Osteo-Clage Wire Clamp	OW-1200
Freer Elevator	MS-57614
15mm, Hohmann Retractor	MS-46827
Rad Tip Periosteal Elevator	MS-46212

General Instruments

2.5mm Quick Release Driver	HPC-0025
3.5mm Screw Driver Sleeve	MS-SS35
Large Cannulated Quick Release Driver Handle	MS-3200
2.8mm x 5", Quick Release Drill	MS-DC28
2.0mm x 5", Quick Release Drill	MS-DC5020
3.5mm x 5", Quick Release Drill	MS-DC35
2.8 x 3.5mm, Narrow Drill Guide	PL-2196
2.0 x 2.8mm, Narrow Drill Guide	PL-2118
2.8mm, Offset Drill Guide	PL-2095
3.5mm, Screw In Drill Guide	MS-LDG35
2.7mm, Screw In Drill Guide	MS-LDG27
6-70 x 2mm, Depth Gauge	MS-9022
.045 x 6", St-Guide Wire	WS-1106ST
.059 x 5", St-Guide Wire	WS-1505ST
Large Congruent Plate Bender	PL-2045
Congruent Plate Bender	PL-2040
2.7mm, Cortical Long Tap Tip	MS-LTT27
3.5mm, Cortical Long Tap Tip	MS-LTT35
Plate Tack	PL-PTACK
Plate Clamp	80-0223
Countersink	PL-2080



REFERENCES

1. Bostman et al, *Journal of Trauma: Injury, Infection, and Critical care*. 1997; 5: 778-783.
2. Huang et al, *Clavicular Anatomy and the Applicability of Precontoured Plates*. *Journal of Bone and Joint Surgery (Am.)* 2007; 89: 2260-2265.
3. Iannotti et al, *Journal of Shoulder and Elbow Surgery*. 2002 September / October; 11 (5): 457-462.
4. Data on file at Acumed.
5. Goswami et al, *Biomechanical evaluation of a pre-contoured clavicle plate*. *Journal of Shoulder and Elbow Surgery*. 2008 September/October; 17 (5): 815-818.
6. Data on file at Acumed.
7. Luo, CE, *Locking compression plating: a new solution for fractures in rheumatoid patients*. *Modern Rheumatology* 2005; 15: 169-172.
8. Brouwer et al, *Failure of superior locking clavicle plate by axial pull-out of the lateral screws: a report of four cases*. *Journal of Shoulder and Elbow Surgery*. 2009 January; 18 (1): e22-e25.
9. Data on file at Acumed.
10. Bishal, S., Plancher, K., Areson, D. *Operative Treatment for Comminuted Midshaft Fractures and Type II Distal Clavicle Fractures With Plating Techniques*. *Fractures of the Upper Extremity*. American Society for Surgery of the Hand. 2008
11. Renner et al, *Scapula and Clavicle*. *AO Principles of Fracture Management*. AO Publishing (Thieme). 2007. 557-571.
12. Bishal et al.
13. Endrizzi, D., White R., Babikian, G., Old, A. et al. *Non-union of the clavicle treated with plate fixation: a review of forty-seven consecutive cases*. *Journal of Shoulder and Elbow Surgery*. 2008 November/December; 17 (6) : 951-953.
14. Bishal et al.
15. Altamimi, S., McKee, M. *Nonoperative Treatment Compared with Plate Fixation of Displaced Midshaft Clavicular Fractures (Surgical Technique)*. *Journal of Bone and Joint Surgery*. 2008; 90 Supplement (part 1): 1-8.
16. Collinge et al, *Anterior-Inferior Plate Fixation of Middle-third Fractures and Nonunions of the Clavicle*. *Journal of Orthopaedic Trauma*. November/December 2006; 20 (10): 680-686.
17. Collinge et al.
18. Yeh, et al, *Midshaft clavicle fracture and acromioclavicular dislocation: A case report of a rare Injury*. *Journal of Shoulder and Elbow Surgery*. 2008 December; Article In Press :1-4.
19. Yeh et al.
20. Bishal et al.

ACUMED®

5885 NW Cornelius Pass Road

Hillsboro, OR 97124

(888) 627-9957

www.acumed.net

Distributed by:

SHD00-00-B

Effective: 7/2009

These materials contain information about products that may or may not be available in any particular country or may be available under different trademarks in different countries. The products may be approved or cleared by governmental regulatory organizations for sale or use with different indications or restrictions in different countries. Products may not be approved for use in all countries. Nothing contained on these materials should be construed as a promotion or solicitation for any product or for the use of any product in a particular way which is not authorized under the laws and regulations of the country where the reader is located. Specific questions physicians may have about the availability and use of the products described on these materials should be directed to their particular local sales representative. Specific questions patients may have about the use of the products described in these materials or the appropriateness for their own conditions should be directed to their own physician.